



## RADIOLOGICAL DIAGNOSIS OF FATTY LIVER AND HEPATOMEGALY IN KSA

Ibrahim Hudaid Almutairi<sup>1</sup>, Mohammad Awadh Alharbi<sup>2</sup>, Faisal Miqad Alharbi<sup>3</sup>, Ali Saeed Alqarni<sup>4</sup>, Trad Hamed Almutairi<sup>5</sup>, Faisal Abdu Moafa<sup>6</sup>, Majed Dakhilallah Almutairi<sup>7</sup>, Faisal Rafe Almutairi<sup>8</sup>

<sup>1</sup>Alsulaimaneah Primary Health Care, Saudi Arabia, [i.alruhaimi@gmail.com](mailto:i.alruhaimi@gmail.com)

<sup>2</sup>King Saud Medical City, Saudi Arabia, [malhrby060@gmail.com](mailto:malhrby060@gmail.com)

<sup>3</sup>Compliance Health Affair, Saudi Arabia, [faisal112010@hotmail.com](mailto:faisal112010@hotmail.com)

<sup>4</sup>Remah General Hospital, Saudi Arabia, [ali404@windowslive.com](mailto:ali404@windowslive.com)

<sup>5</sup>Health Affairs in Riyadh, Saudi Arabia, [tradhamed@hotmail.com](mailto:tradhamed@hotmail.com)

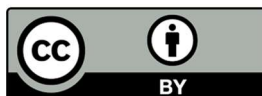<sup>6</sup>Salhudeen primary Health Care, Saudi Arabia, [faisalmaofa21@hotmail.com](mailto:faisalmaofa21@hotmail.com)

<sup>7</sup>Health Affairs in Riyadh, Saudi Arabia, [majedalmutiri@hotmail.com](mailto:majedalmutiri@hotmail.com)

<sup>8</sup>Health Affairs in Riyadh, Saudi Arabia, [faisalrafe@gmail.com](mailto:faisalrafe@gmail.com)

### Abstract

**Background:** Fatty liver disease (FLD), whether it is alcoholic FLD (AFLD) or nonalcoholic FLD (NAFLD), encompasses a morphological spectrum consisting of hepatic steatosis (fatty liver) and steatohepatitis. CT scans provide a non-invasive means of diagnosing the presence and severity of NAFLD. Objective: to estimate the prevalence of diffuse fatty liver disease and if there a relationship between diffuse fatty liver disease and hepatomegaly, among patients under routine CT scan different Hospitals in Saudi Arabia. **Methods:** It was a cross sectional study. We examined 158 adults aged 21-55 years, with mean age ( $\pm$ SD) of was 41.55 ( $\pm$ 9.08). They attend the radiology department for routine CT scanning KUB, all cases with poor quality scan was not included. A chick list was used in data collection, it contains; age, sex, fatty liver (HU<40), hepatic density and liver size (in cm). **Results:** about tow thirds of the studied participants (63.9%) were males. Fatty liver (HU<40) was found in 24 (15.2%) of the studied participants. Hepatic density measured by Hounsfield Unit (HU) was < 40 HU in 15.2% and > 40 HU in 84.8%. Liver size (in Cm) was 15-18 (hepatomegaly) in 17.7% and  $\leq$  15 in 82.3% of the studied participants. the relation between sex and fatty liver was insignificant ( $P>0.05$ ). The majority (41.7%) of fatty liver cases were from the age group 31-40 years, then 33.3% from 41-50 years but the relation between age and fatty liver was also insignificant ( $P>0.05$ ). More than 2 thirds (70.8%) of fatty liver cases had hepatomegaly (liver size 15 -18Cm) and the relation between fatty liver and liver size was highly



All the articles published by Chelonian Conservation and Biology are licensed under a [Creative Commons Attribution-NonCommercial 4.0 International License](https://creativecommons.org/licenses/by-nc/4.0/) Based on a work at <https://www.acgpublishing.com/>

significant ( $P < 0.01$ ). **Conclusion:** The use of liver attenuation values will be useful to assess the diagnosis of Fatty liver and hepatomegaly, so it is a reliable device in further studies as in follow up of the same participants.

**Key words:** Computed Tomography, Fatty Liver, Hepatomegaly, Saudi Arabia.

### **Introduction:**

Fatty liver, or hepatic steatosis or simple steatosis, is a disease where surplus adipose, mainly triglycerides, compiles to make more than 5% of the hepatic weight [1]. The two most common conditions of fatty liver are alcoholic fatty liver disease (AFLD) and nonalcoholic fatty liver disease (NAFLD). Alcoholic fatty liver disease is caused by excess alcohol consumption, while the nonalcoholic variant is related to insulin resistance and the metabolic syndrome [2,3].

NAFLD is becoming a global health problem in adults as well as children and is rapidly becoming the leading indication for liver transplantation. NAFLD patients are at increased risk of liver-related as well as cardiovascular mortality [4].

obesity-associated insulin resistance appears to serve as a pathogenic event responsible for the metabolic syndrome comprising Type 2 diabetes mellitus, dyslipidemia, atherosclerosis, hypertension, and hepatic steatosis progressing to NAFLD [5]. NAFLD can also be associated with many causes other than metabolic syndrome; Drugs and toxins (e.g. amiodarone), severe weight loss, refeeding syndrome, celiac disease, inflammatory bowel disease, HIV, and hepatitis C (especially genotype 3) [6,7].

Fatty liver disease (FLD), whether it is alcoholic FLD (AFLD) or nonalcoholic FLD (NAFLD), encompasses a morphological spectrum consisting of hepatic steatosis (fatty liver) and steatohepatitis. This more severe condition, steatohepatitis, may be termed either alcoholic steatohepatitis or non-alcoholic steatohepatitis (NASH). [8]

Fat accumulation is one of the commonest liver abnormalities among patients undergoing cross-sectional imaging of the abdomen. The prevalence of fatty liver in the general population is about 15%, but it is higher among those who consume large quantities ( $>60$  g per day) of alcohol (45%), those with hyperlipidemia (50%) or obesity (body mass index  $>30$ ) (75%), and those with both obesity and high alcohol consumption (95%) [9,10].

various imaging methods have been utilized to Diagnose patients with fatty liver, including ultrasonography (US), computed tomography (CT), magnetic resonance imaging (MRI), and magnetic resonance spectroscopy (MRS), with these methods mostly used to quantify hepatic steatosis [11].

At unenhanced CT, a normal liver has slightly greater attenuation than the spleen and blood, and intrahepatic vessels are visible as relatively hypo attenuated structures. Fatty liver can be diagnosed if computed tomography shows lower density in liver than spleen (attenuation of the

liver at least 10 HU less than that of the spleen), or if the attenuation of the liver is less than 40 HU [12-13].

In the study of Gasim et al. [14] who aimed to examine the link between liver fat infiltration and abdominal fat amount using plain computer-assisted tomography (CT), he found that plain computed tomography can reliably be used as a survey device for fatty liver disease as his study has added to the evidence of the utility of plain computed tomography in the diagnosis of non-alcoholic steatohepatitis where one of its main findings is the moderate negative correlation between the liver attenuation indices and the body mass index.

The aim of this study was to estimate the prevalence of diffuse fatty liver disease and if there a relationship between diffuse fatty liver disease and hepatomegaly, among patients under routine CT scan in different Hospitals in Saudi Arabia during the period from 1 May to 31 July 2019.

## **Methods:**

### **Study type, sitting and period:**

It was a cross sectional study, conducted in the radiology department of different Hospitals in Saudi Arabia during the period the period from 1 May to 31 July 2019.

### **Data collection:**

We examined 158 adults aged 21-55 years, with mean age ( $\pm$ SD) of was 41.55 ( $\pm$ 9.08). They attend the radiology department for routine CT scanning KUB, all cases with poor quality scan was not included.

At unenhanced CT, the normal liver has slightly greater attenuation than the spleen and blood, and intrahepatic vessels are visible as relatively hypo-attenuated structures. Spleen is usually present at the same level as that of liver. Since spleen is devoid of fat, it can be used as an internal control for the degree of penetrance of the scan and the image quality. Fatty liver can be diagnosed if the attenuation of the liver is at least 10 HU less than that of the spleen <sup>[15]</sup> or if the attenuation of the liver is less than 40 HU <sup>[16]</sup> and intrahepatic vessels may appear hyper-attenuated relative to the fat-containing liver tissue in severe cases of fatty liver. liver size was also measured in cm, hepatomegaly was considered if the liver size was  $> 15\text{cm}$  <sup>[17]</sup>.

A check list was used in data collection, it contains; age, sex, fatty liver (HU $<$ 40), hepatic density and liver size (in cm).

### **Ethical consideration:**

The participants was assured that their data was dealt with confidentiality. Written informed consent after explaining the purpose of the study was obtained from all patients who participated in the study. The check list used in data collection were anonymous and confidentiality of data was assured.

### The statistical analysis:

Data entry and statistical analysis was carried out using SPSS (statistical package for social sciences, Version 16). participants characteristics were summarized as numbers and percentages for qualitative variables. Chi-Square test and independent sample t test were used for testing of the associations. A 5% level was considered as a level of statistical significance in all statistical tests used in the study.

### Results:

Table 1 shows the age, sex, fatty liver (HU<40), hepatic density and liver size (Cm) in the studied participants. It is clear from the table that, the age of the studied participants ranged from 21-55 years. The Mean age ( $\pm$ SD) of the studied cases was 41.55 ( $\pm$ 9.08). about tow thirds of the studied participants (63.9%) were males. Fatty liver (HU<40) was found in 24 (15.2%) of the studied participants. Hepatic density measured by Hounsfield Unit (HU) was < 40 HU in 15.2% and > 40 HU in 84.8%. Liver size (in Cm) was 15-18 (hepatomegaly) in 17.7% and  $\leq$  15 in 82.3% of the studied participants.

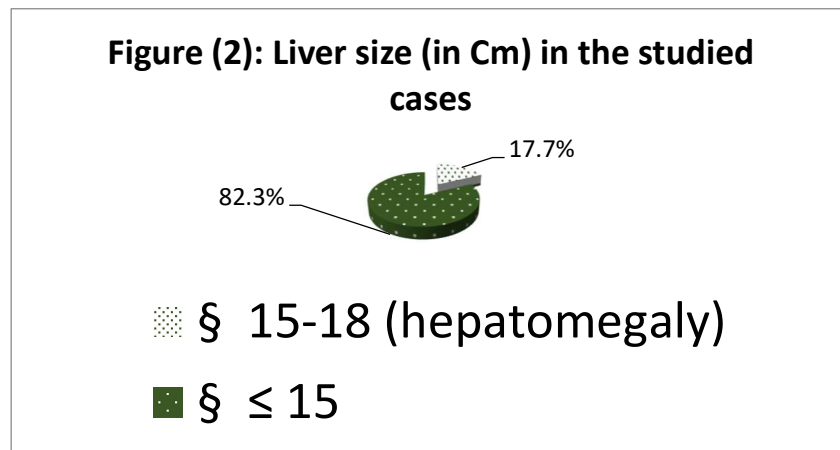
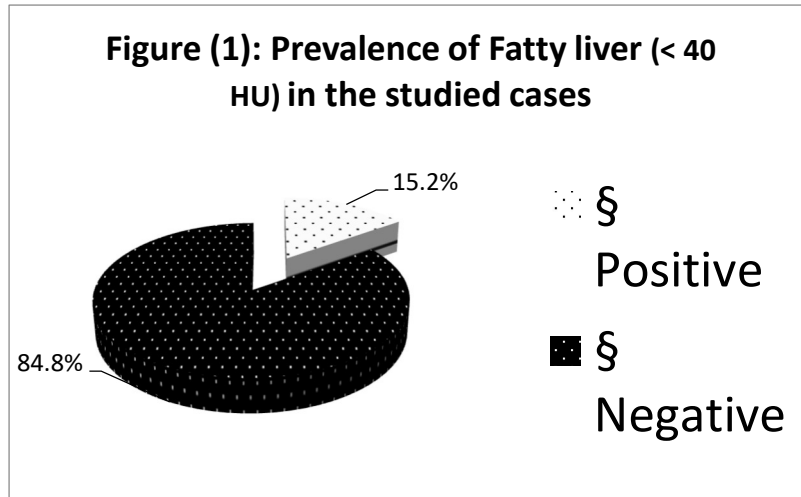
Table (2): Hepatic density measured by Hounsfield Unit (HU) in fatty liver cases. Hepatic density measured by Hounsfield Unit (HU) in fatty liver cases was 36-39 HU in 33.3%, 33-35 HU in 37.5% and 27-32 HU in 29.2% of cases.

Table 3 illustrates the relationship between fatty liver and sex, age and liver size in the studied cases. It is clear from the table that, tow thirds (66.7%) of the fatty liver cases were males but the relation between sex and fatty liver was insignificant ( $P>0.05$ ). The majority (41.7%) of fatty liver cases were from the age group 31-40 years, then 33.3% from 41-50 years but the relation between age and fatty liver was also insignificant ( $P>0.05$ ). more than 2 thirds (70.8%) of fatty liver cases had hepatomegaly (liver size 15 -18Cm) and the relation between fatty liver and liver size was highly significant ( $P<0.01$ ).

**Table (1): age, sex, fatty liver (HU<40), hepatic density and liver size (Cm) in the studied participants, Najran, 2018**

Parameters	Frequency (No.)	Percent (%)
Age range	21-55	
Mean age ( $\pm$ SD)	41.55 $\pm$ 9.08	
<b>Sex</b>		
▪ Male	101	63.9
▪ Female	57	36.1
<b>Fatty liver (HU&lt;40)</b>		
▪ Positive	24	15.2
▪ Negative	134	84.8
<b>Hepatic density measured by Hounsfield Unit (HU)</b>		

▪ < 40 HU	24	15.2
▪ > 40 HU	134	84.8
<b>Liver size (in Cm)</b>		
▪ 15-18 (hepatomegaly)	28	17.7
▪ ≤ 15	130	82.3



**Table (2): Hepatic density measured by Hounsfield Unit (HU) in fatty liver cases, Najran, 2018**

Hepatic density measured by Hounsfield Unit (HU)	Frequency	Percent
27-32 HU	7	29.2
33-35 HU	9	37.5
36-39 HU	8	33.3
Total	24	100.0

**Table (3): the relationship between fatty liver and sex, age and liver size in the studied cases, Najran, 2018**

Parameter		Fatty liver (HU<40)		Total (N=158)	P value
		Positive (N=24)	Negative (N = 134)		
Sex	Male	16	85	101	0.47
		66.7%	63.4%	63.9%	
	Female	8	49	57	
		33.3%	36.6%	36.1%	
Age group	21-30	2	17	19	0.85
		8.3%	12.7%	12.0%	
	31-40	10	45	55	
		41.7%	33.6%	34.8%	
	41-50	8	49	57	
		33.3%	36.6%	36.1%	
	>50	4	23	27	
		16.7%	17.2%	17.1%	
<b>Mean (±SD)</b>		41.54 ± 7.87	41.55±9.31	41.55±9.08	0.993*
Liver size (in Cm)	>15 (hepatomegaly)	17	11	28	0.001
		70.8%	8.2%	17.7%	
	≤ 15	7	123	130	
		29.2%	91.8%	82.3%	

\* calculated using t test

**Discussion:**

Fat accumulation is one of the most common abnormalities of the liver depicted on cross-sectional images of the abdomen. The estimated prevalence of nonalcoholic fatty liver disease (NAFLD) in Saudi Arabia is 7% to 10% [18].

Diagnosis of fatty liver usually is straightforward, but fat accumulation may be manifested with unusual structural patterns that mimic neoplastic, inflammatory, or vascular conditions. CT scans provide a non-invasive means of diagnosing the presence and severity of NAFLD [16].

A study was performed by Longo et al. [19] to compare magnetic resonance spectroscopy with computed tomography and histological assessment for the diagnosis of fatty liver. They compared L/S ratio with different grades of fatty infiltration of liver and found a good correlation between CT and histology ( $R = 0.77$ ,  $p < 0.001$ ).

Another study performed by Kodama et al. [6] in order to determine the severity of fat content on CT scans. They compared unenhanced and contrast enhanced CT scans with histological diagnosis of fatty liver, and they found that liver attenuation 40 HU on non-enhanced CT scans corresponds with about 30% liver fat content whereas liver attenuation 30 HU corresponds to about 50% liver fat content. In this study we depended mainly on measuring the liver attenuation using CT scan.

The aim of this study was to estimate the prevalence of diffuse fatty liver disease and if there a relationship between diffuse fatty liver disease and hepatomegaly, among patients under routine CT scan in different Hospitals in Saudi Arabia during the period from 1 May to 31 July 2019. We reviewed most of cases done in our hospital by routine CT scan KUB, and all cases with poor quality scan was excluded.

Our sample consisted of 158 patients of both sexes, 63.9% of them were males.

In the current study, the total percentage of the positive cases of fatty liver ( $HU < 40$ ) was 15.2%. The Hepatic density in fatty liver cases varied from 27 to 39 HU. This result is similar to Okka W. Hamer's [20]. While Al-hamoudi W. et al. [18] found in their study a higher percentage of fatty liver (16.6%) in their sample.

In the current study we found a negative relation between sex ( $P=0.47$ ), age group ( $P=0.85$ ) and the liver attenuation indices, while there was a strong significant relation ( $P=0.001$ ) between hepatomegaly and fatty liver. 17.7% of total sample and 70.8% of the positive sample had hepatomegaly (liver size  $>15$  cm). Our findings are in accordance with Al-hamoudi W. et al. [18] who evaluate the role of CT scans in liver fat measurements in Saudi Arabia.

## **Conclusion:**

The use of liver attenuation values will be useful to assess the diagnosis of Fatty liver and hepatomegaly, so it is a reliable device in further studies as in follow up of the same participants.

## References:

1. Kneeman JM, Misdraji J, Corey KE. Secondary causes of nonalcoholic fatty liver disease. *Therapeutic Advances in Gastroenterology*. 2012;5:199–207.
2. Adams LA, Lymp JF, Sauver JS, Sandeson SO, Lindor KD, Feldstein A, and Angulo P. *Gastroenterology* 129: 113-2005.
3. Browning JD, Szczepaniak LS, Dobbins R, Nuremberg P, Horton JD, Cohen JC, Grundy SM, and Hobbs HH. *Hepatology* 40: 1387-2004.
4. Evans RM, Barish GD, Wang YX. (2004): PPARs and the complex journey to obesity. *Nat Med.*, (10):355–361.
5. Reddy JK, Rao M. (2006): Lipid Metabolism and Liver Inflammation. II. Fatty liver disease and fatty acid oxidation. *American Journal of Physiology*, 290(5): 852-8.
6. Osman KA, Osman MM, Ahmed MH (January 2007). "Tamoxifen-induced non-alcoholic steatohepatitis: where are we now and where are we going?". *Expert Opinion on Drug Safety*. 6 (1): 1–4
7. Valenti L, Dongiovanni P, Piperno A, Fracanzani AL, Maggioni M, Rametta R, Loria P, Casiraghi MA, Suigo E, Ceriani R, Remondini E, Trombini P, Fargion S (2006). "Alpha 1-antitrypsin mutations in NAFLD: high prevalence and association with altered iron metabolism but not with liver damage". *Hepatology*. 44 (4): 857–64.
8. Hamaguchi M, Kojima T, Takeda N, Nakagawa T, Taniguchi H, Fujii K, Omatsu T, Nakajima T, Sarui H, Shimazaki M, Kato T, Okuda J, and Ida K. *Ann Intern Med* 143: 722-2005.
9. Bellentani S, Saccoccio G, Masutti F, et al. Prevalence of and risk factors for hepatic steatosis in Northern Italy. ***Ann Intern Med***2000; 132: 112–117
10. Kammen BF, Pacharn P, Thoeni RF, et al. Focal fatty infiltration of the liver: analysis of prevalence and CT findings in children and young adults. ***AJR Am J Roentgenol***2001; 177: 1035–1039.
11. Lee, S. S., & Park, S. H. (2014). Radiologic evaluation of nonalcoholic fatty liver disease. *World Journal of Gastroenterology* : WJG, 20(23), 7392–7402.
12. Siddharth S, Sudhakar VK, Rohit L et al. (2015). "Magnetic resonance elastography for staging liver fibrosis in non-alcoholic fatty liver disease: a diagnostic accuracy systematic review and individual participant data pooled analysis". *European Radiology*. 26 (5): 1431–1440.
13. Hamer OW, Aguirre DA, Casola G, Sirlin CB. Imaging features of perivascular fatty infiltration of the liver: initial observations. *Radiology*2005; 237: 159–169.
14. Gasim, G. I., Elshehri, F. M., Kheidr, M., Alshubaily, F. K., ElZaki, E. M., & Musa, I. R. (2017). The Use of Computed Tomography in the Diagnosis of Fatty Liver and Abdominal Fat Distribution among a Saudi Population. *Open Access Macedonian Journal of Medical Sciences*, 5(6): 762–765.



15. Limanond P, Raman SS, Lassman C, et al. Macrovesicular hepatic steatosis in living related liver donors: correlation between CT and histologic findings. *Radiology* 2004; 230: 276–280. Link, Google Scholar
16. Hamer OW, Aguirre DA, Casola G, Sirlin CB. Imaging features of perivascular fatty infiltration of the liver: initial observations. *Radiology* 2005; 237: 159–169. Link, Google Scholar
17. Joy D, Thava VR, Scott BB. Diagnosis of fatty liver disease: is biopsy necessary? *Eur J Gastroenterol Hepatol* 2003; 15: 539–543. Crossref, Medline, Google Scholar
18. Al-hamoudi W. et al. Epidemiological, clinical, and biochemical characteristics of Saudi patients with nonalcoholic fatty liver disease: a hospital-based study. *Ann Saudi Med.* 2012 May-Jun;32(3):288-92. doi: 10.5144/0256-4947.2012.288.
19. Longo R, Ricci C, Masutti F, et al. Fatty infiltration of the liver. Quantification by <sup>1</sup>H localized magnetic resonance spectroscopy and comparison with computed tomography. *Invest Radiol.* 1993;28(4):297–302. [PubMed]
20. Kodama Y, Ng CS, Wu TT, et al. Comparison of CT methods for determining the fat content of the liver. *AJR Am J Roentgenol.* 2007;188(5):1307–12. [PubMed].
21. Okka W. Hamer. Et al. Fatty Liver: Imaging Patterns and Pitfalls. *RadioGraphics.* Published Online: Nov 1 2006 <https://doi.org/10.1148/rg.266065004>.